

MERCY URGENT CARE CENTRE

ST. Mary's Health Campus, Bakers Road, Gurrabraher, Cork T23YV52

Tel: +353 (21) 4926900 / 4926901

Fax: +353 (21) 4248114

www.muh.ie

Suspected Scaphoid Fracture Patient Information

Some anatomy around your wrist

The scaphoid bone is one of the largest carpal (wrist) bones and is on the thumb side of your wrist.

What is a scaphoid fracture and what is the usual cause?

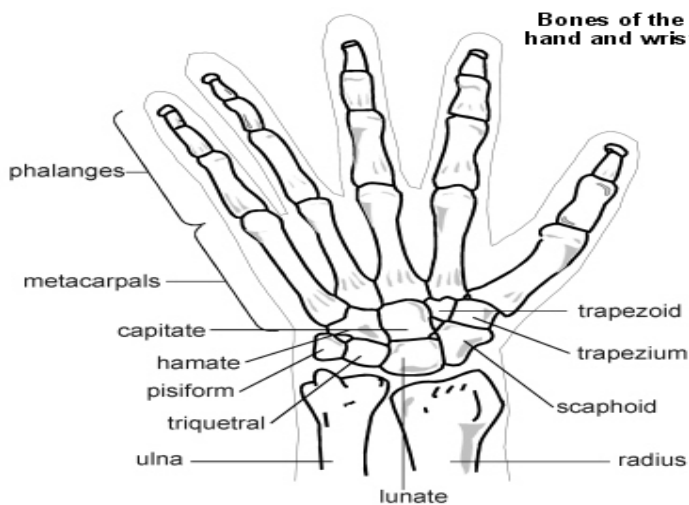
A scaphoid fracture is when you break your scaphoid bone. It most commonly happens after a fall on to your outstretched hand. Sometimes a direct blow to the palm of your hand can cause a scaphoid fracture. Occasionally repeated stress on the scaphoid bone can lead to a fracture. Scaphoid fractures may be non-displaced (the fragments of the broken bone haven't moved out of position) or displaced (there is some movement of the bone fragments).

How common is a Scaphoid Fracture?

The scaphoid bone is the most commonly fractured carpal bone. This is because of its size and position in the two rows of carpal bones in your hand.

What are the symptoms of a scaphoid fracture diagnosed?

Usually most people with a scaphoid fracture will remember a specific injury or fall. In some people symptoms may be milder. Quite commonly people with a scaphoid fracture just assume that they have sprained their wrist and they don't seek medical attention for some time afterwards. The fracture may only be diagnosed when they see a doctor some weeks later because of pain that is not setting or reduced movement around their wrist.



How is a scaphoid fracture diagnosed?

It can sometimes be quite difficult to diagnose a scaphoid fracture. Standard x-rays may not pick up all scaphoid fractures. This is because the scaphoid bone can hide behind the other carpal bones on an x-ray. Special scaphoid view x-rays taken with your hand and wrist in a certain position may help to show up a scaphoid fracture. However between 1 and 2 in 10 scaphoid fractures may not be seen on x-ray.

In some cases a scaphoid fracture will not show up on an x-ray until around 10 to 14 days after the initial injury. At this time the healing process will have started in the bone which will help the fracture site to show up. So if a scaphoid fracture is suspected but not confirmed on an initial x-ray you will usually be treated as if you have a scaphoid fracture and a repeat x-ray may be suggested after 10 to 14 days. Treatment usually involves a thumb brace called a 'Futura splint'. Sometimes at this time it is still not clear whether you have a scaphoid fracture. If this the case an MRI scan may be suggested to look for the fracture. A radionuclide bone scan is occasionally used as an alternative.

What is the treatment of a Scaphoid Fracture?

If a non-displaced scaphoid fracture is confirmed on x-ray it is usually treated by putting your arm in a cast. The cast is usually worn for 8 to 12 weeks until the scaphoid bone heals.